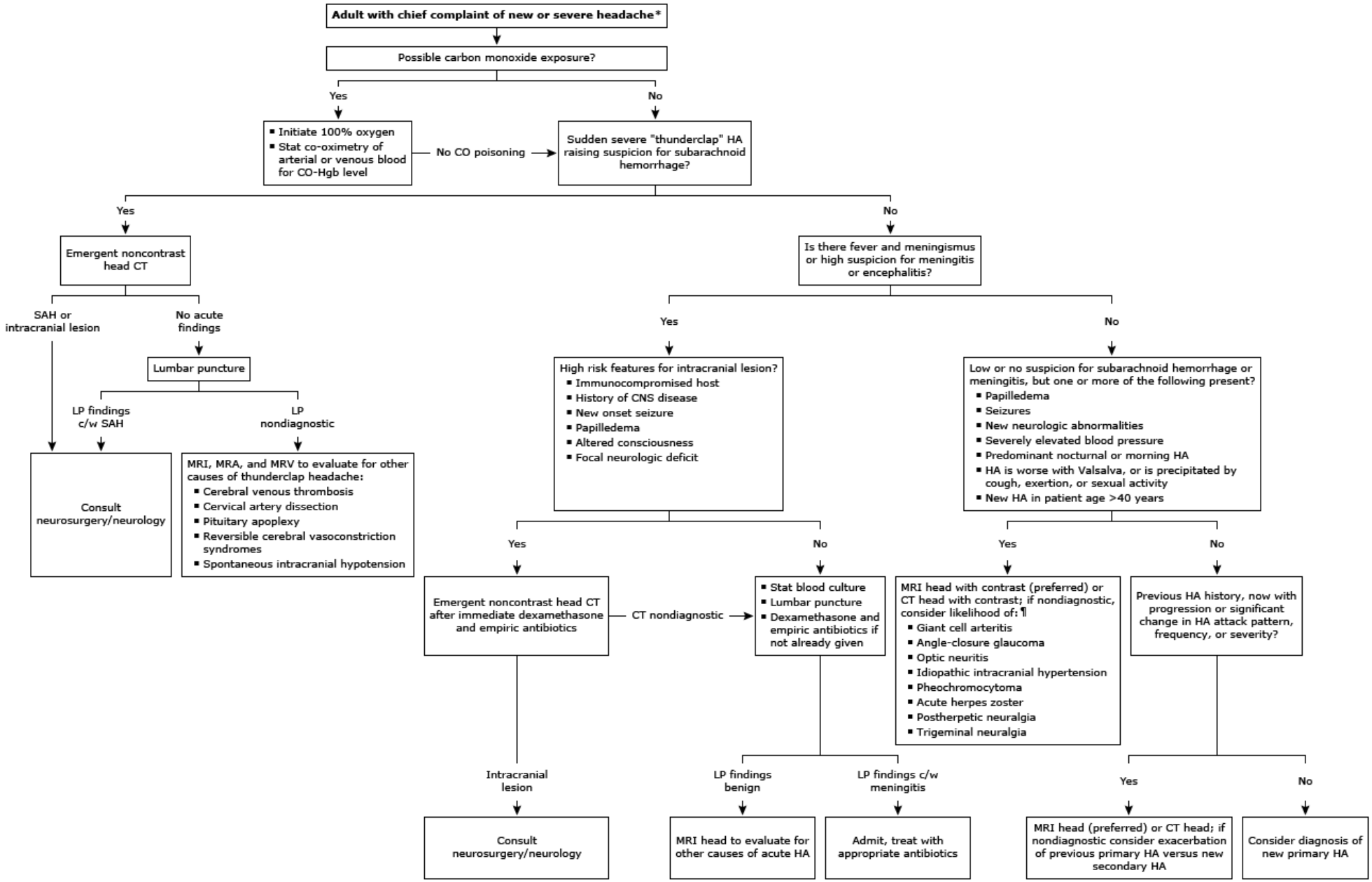
Adult with chief complaint of new or severe headache*
Possible carbon monoxide exposure?
Yes
No
Initiate 100% oxygen
Stat co-oximetry of arterial or venous blood for CO-Hgb level
No CO poisoning
Sudden severe "thunderclap" HA raising suspicion for subarachnoid hemorrhage?
Yes
No
Emergent noncontrast head CT
SAH or intracranial lesion
No acute findings
Lumbar puncture
LP findings c/w SAH
LP nondiagnostic
Consult neurosurgery/neurology
MRI, MRA, and MRV to evaluate for other causes of thunderclap headache:
Cerebral venous thrombosis
Cervical artery dissection
Pituitary apoplexy
Reversible cerebral vasoconstriction syndromes
Spontaneous intracranial hypotension
Is there fever and meningismus or high suspicion for meningitis or encephalitis?
Yes
No
High risk features for intracranial lesion?
Immunocompromised host
History of CNS disease
New onset seizure
Papilledema
Altered consciousness
Focal neurologic deficit
Low or no suspicion for subarachnoid hemorrhage or meningitis, but one or more of the following present?
Papilledema
Seizures
New neurologic abnormalities
Severely elevated blood pressure
Predominant nocturnal or morning HA
HA is worse with Valsalva, or is precipitated by cough, exertion, or sexual activity
New HA in patient age >40 years
Yes
No
Yes
No
Emergent noncontrast head CT after immediate dexamethasone and empiric antibiotics
CT nondiagnostic
Stat blood culture
Lumbar puncture
Dexamethasone and empiric antibiotics if not already given
MRI head with contrast (preferred) or CT head with contrast; if nondiagnostic, consider likelihood of: ¶
Giant cell arteritis
Angle-closure glaucoma
Optic neuritis
Idiopathic intracranial hypertension
Pheochromocytoma
Acute herpes zoster
Postherpetic neuralgia
Trigeminal neuralgia
Previous HA history, now with progression or significant change in HA attack pattern, frequency, or severity?
Intracranial lesion
LP findings benign
LP findings c/w meningitis
Yes
No
Consult neurosurgery/neurology
MRI head to evaluate for other causes of acute HA
Admit, treat with appropriate antibiotics
MRI head (preferred) or CT head; if nondiagnostic consider exacerbation of previous primary HA versus new secondary HA
Consider diagnosis of new primary HA