

COVID-19–Associated Croup in Children

Ryan CL Brewster, MD,^{a,b} Chase Parsons, DO, MBI,^a Jess Laird-Gion, MD,^{a,b} Sidney Hilker, MD,^{a,b} Margaret Irwin, MD,^{a,b} Alba Sommerschild, MD,^{a,b} Katherine A Michaelis, MD, PhD,^{a,b} Michael Lam, MD, PhD,^{a,b} Andrew Parsons, MD,^{a,b} Jonathan M Mansbach, MD, MPH^a

As severe acute respiratory syndrome coronavirus 2 (SARS-CoV-2) has evolved, so has its effects on the pediatric population.¹ Although early variants typically resulted in lower respiratory infections, the recently identified *o* variant may exhibit a predilection for the upper airways.² The relatively smaller upper respiratory tract in children compared to adults has been thought to predispose them to more severe clinical presentations resembling laryngotracheobronchitis, or croup. Caused by viral-induced subglottic airway inflammation, croup is classically characterized by sudden onset “barking cough,” inspiratory stridor, and respiratory distress. Endemic coronaviruses have been linked to croup; however, only sparse case reports have described croup specifically associated with SARS-CoV-2, and it remains unclear if croup cases constitute a causative relationship or result of coinfection with another virus.^{3–6} To address this knowledge gap, we performed a retrospective analysis of the incidence and clinical characteristics of croup associated with SARS-CoV-2 infection at a large freestanding children’s hospital.

METHODS

Clinical and demographic characteristics and viral testing data were obtained from medical record data from a freestanding children’s hospital in Boston, Massachusetts between March 1, 2020 and January 15, 2022. Inclusion criteria were a

diagnosis of coronavirus 2019 (COVID-19) by real-time polymerase chain reaction with a recorded International Classification of Diseases, Tenth Revision code for laryngotracheitis (J05.0, R05, R05.8, J38.7) during the same hospital encounter. We limited our analysis to patients treated in the emergency department and discharged (“emergency department”) and those requiring inpatient hospitalization (“hospitalized”). Abstracted data were corroborated with manual chart review.

We used descriptive statistics to summarize patient characteristics and outcomes. We defined the *o* period as starting on December 4, 2021, corresponding to the first documented case of the *o* variant in Massachusetts. Median weekly cases during the omicron and pre-omicron periods were compared by using the Wilcoxon rank test. This study received institutional review board approval.

RESULTS

Between March 1, 2020 and January 15, 2022, a total of 75 children were diagnosed with COVID-19–associated croup, 81% of whom presented during the omicron period (Fig 1). There was a significant difference in median weekly cases between the pre-omicron (0 [interquartile range (IQR) 0–0]) and omicron periods (11 [IQR 2–17]) ($P < .001$). Most patients were male (72%) and discharged from the emergency department (88%) (Table 1). All

^aDepartment of General Pediatrics, Boston Children’s Hospital, Boston, Massachusetts; and ^bDepartment of General Pediatrics, Boston Medical Center, Boston, Massachusetts

Dr Brewster conceptualized and designed the study, collected the data, carried out initial analyses, and reviewed and revised the manuscript; Dr Parsons collected the data, carried out initial analyses, and reviewed and revised the manuscript; Drs Laird-Gion, Hilker, Irwin, and Sommerschild drafted the initial manuscript, and reviewed and revised the manuscript; Drs Michaelis, Lam, and Parsons contributed to study design and data analysis, and reviewed and revised the manuscript; Dr Mansbach conceptualized and designed the study, coordinated and supervised data collection and analysis, and critically reviewed the manuscript for important intellectual content; and all authors approved the final manuscript as submitted and agree to be accountable for all aspects of the work.

DOI: <https://doi.org/10.1542/peds.2022-056492>

Accepted for publication Mar 4, 2022

Address correspondence to Ryan Brewster, MD, Department of Pediatrics, Boston Children’s Hospital, 300 Longwood Ave, Boston, MA 02115. E-mail: ryan.brewster@childrens.harvard.edu

PEDIATRICS (ISSN Numbers: Print, 0031-4005; Online, 1098-4275).

Copyright © 2022 by the American Academy of Pediatrics

FUNDING: No external funding.

CONFLICT OF INTEREST DISCLOSURES: The authors indicated they have conflicts of interest relevant to this article to disclose.

To cite: Brewster RC, Parsons C, Laird-Gion J, et al. COVID-19–Associated Croup in Children. *Pediatrics*. 2022;149(6):e2022056492

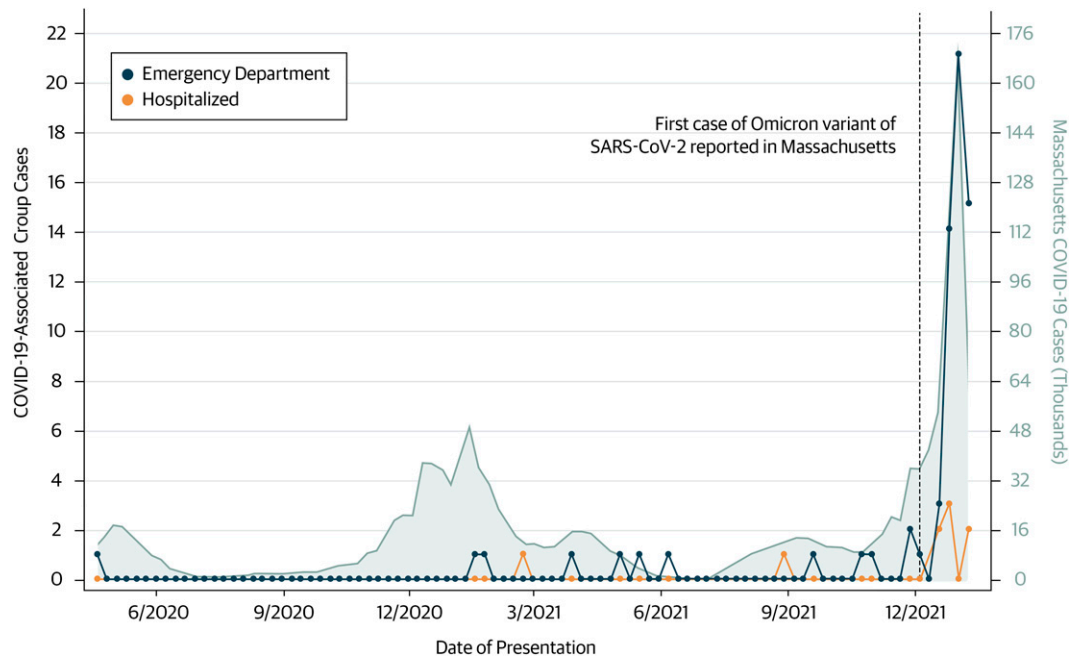


FIGURE 1

Weekly emergency department and hospitalized cases of COVID-19-associated croup in children compared with overall burden of COVID-19 in Massachusetts (Massachusetts Department of Public Health) through January 15, 2022.

children tested for other viral infections were negative except for one with rhinovirus. Dexamethasone was administered to 97% of patients. Whereas 100% of hospitalized patients received racemic epinephrine, it was given to

only 25% of patients treated in the emergency department. Among hospitalized patients, the median length of stay was 1.7 days (IQR 1.3–2.3 days), and the median number of dexamethasone and racemic epinephrine doses was 6

(IQR 4–9) and 8 (IQR 2–10), respectively. Four patients required intensive care, with one escalating to helium-oxygen mixture and continuous positive airway pressure. No patients required invasive ventilation or died.

TABLE 1 Characteristics of Children Diagnosed With COVID-19–Associated Croup

	Pre-Omicron (Before December 4, 2021)		Omicron (After December 4, 2021)	
	Emergency Department <i>n</i> = 12	Hospitalized <i>n</i> = 2	Emergency Department <i>n</i> = 54	Hospitalized <i>n</i> = 7
Median age (IQR)	2.6 (1.6–3.4)	1.3 (1.1–1.5)	2.4 (0.8–2.6)	1.6 (0.7–1.1)
Female sex (%)	4 (33.3)	1 (50)	10 (18.5)	6 (85.7)
Race and ethnicity (%) ^a				
Black, Non-Hispanic	1 (8.3)	1 (50)	8 (14.8)	0 (0)
Hispanic	4 (33.3)	0 (0)	16 (29.6)	2 (28.6)
Other ^b	6 (50)	0 (0)	20 (37)	0 (0)
White, Non-Hispanic	1 (8.3)	1 (50)	10 (18.5)	5 (71.4)
Received viral testing (%) ^c				
Adenovirus	1 (8.3)	1 (50)	4 (7.4)	4 (57.1)
HMPV	1 (8.3)	1 (50)	3 (5.6)	4 (57.1)
Influenza A/B	6 (50)	2 (100)	40 (74.1)	6 (85.7)
Parainfluenza 1/2/3/4	1 (8.3)	1 (50)	4 (7.4)	4 (57.1)
Rhinovirus	1 (8.3)	1 (50)	3 (5.6)	4 (57.1)
RSV	6 (50)	2 (100)	36 (66.7)	6 (85.7)
Dexamethasone (%)	12 (100)	2 (100)	52 (96.3)	7 (100)
Racemic epinephrine (%)	4 (33.3)	2 (100)	15 (27.8)	7 (100)

^a Race and ethnicity information was obtained from patient and family reported data at the time of registration documented in the electronic medical record.

^b "Other" includes Asian, American Indian, and multiracial children as well as those whose racial or ethnic identity was not recorded.

^c All children tested for other viral infections were negative, except for one with rhinovirus.

DISCUSSION

This retrospective analysis of a freestanding children's hospital found that the incidence of croup cooccurring with SARS-CoV-2 infection sharply increased in December 2021, strongly correlating with emergence of the omicron variant. Other spikes in COVID-19 were not associated with increased diagnoses of croup. Interestingly, the observed rates of hospitalization and redosing of croup-directed therapies may indicate a more severe phenotype compared to other viral etiologies.⁷ Taken together; our preliminary findings lend compelling evidence to the hypothesis that the omicron variant causes laryngotracheobronchitis. This tropism shift may stem from differences in protein expression between cells of the lower respiratory versus upper respiratory tract, although variant-specific mechanistic studies remain an active research area.^{8–10}

This study has potential limitations. We conducted our analysis at a single center with a small sample size, potentially restricting its generalizability. Nonetheless, to our knowledge, it remains among the first and largest investigations of COVID-19-associated croup to date. An additional limitation is the absence of viral genotyping. The rapidity with which omicron became the most dominant SARS-CoV-2

variant, however, lowers concern that there was significant local circulation of other strains. Lastly, because comprehensive viral testing was not available, we cannot entirely exclude the possibility of viral coinfection.

Two years into the COVID-19 pandemic, the pathogenicity, infectivity, and manifestations of new variants of SARS-CoV-2 have been dynamic and unique. Croup may represent yet another such novel presentation. Further research is needed to characterize the underlying mechanisms of COVID-19-associated croup, differences in clinical features from other viral etiologies, and appropriate management strategies in the SARS-CoV-2 era.

ABBREVIATIONS

COVID-19: coronavirus disease
2019
SARS-CoV-2: severe acute
respiratory
syndrome
coronavirus 2

REFERENCES

1. Gaythorpe KAM, Bhatia S, Mangal T, et al. Publisher correction: Children's role in the COVID-19 pandemic: a systematic review of early surveillance data on susceptibility, severity, and transmissibility. *Sci Rep*. 2021;11(1):18814
2. Diamond M, Halfmann P, Maemura T, et al. The SARS-CoV-2 B.1.1.529 omicron virus causes attenuated infection and disease in mice and hamsters. *Res Sq*. 2021;rs.3.rs-1211792
3. Pitstick CE, Rodriguez KM, Smith AC, Herman HK, Hays JF, Nash CB. A curious case of croup: laryngotracheitis caused by COVID-19. *Pediatrics*. 2021;147(1):e2020012179
4. Venn AMR, Schmidt JM, Mullan PC. Pediatric croup with COVID-19. *Am J Emerg Med*. 2021;43:287.e1–287.e3
5. Lim CC, Saniasaya J, Kulasegarah J. Croup and COVID-19 in a child: a case report and literature review. *BMJ Case Rep*. 2021;14(9):e244769
6. van der Hoek L, Sure K, Ihorst G, et al. Croup is associated with the novel coronavirus NL63. *PLoS Med*. 2005;2(8):e240.
7. Smith DK, McDermott AJ, Sullivan JF. Croup: diagnosis and management. *Am Fam Physician*. 2018;97(9):575–580
8. McMahan K, Giffin V, Tostanoski LH, et al. Reduced pathogenicity of the SARS-CoV-2 omicron variant in hamsters. *Med (N Y)*. 2022;3(4):262–268.e4
9. Meng B, Ferreira IATM, Abdullahi A, et al. SARS-CoV-2 omicron spike mediated immune escape and tropism shift. *Microbiology*. 2022;rs.3.rs-1191837
10. Peacock TP, Brown JC, Zhou J, et al. The SARS-CoV-2 variant, omicron, shows rapid replication in human primary nasal epithelial cultures and efficiently uses the endosomal route of entry. *Microbiology*. 2022; In press