

JAMA Insights

Coronary Microvascular Dysfunction Causing Cardiac Ischemia in Women

Janet Wei, MD; Susan Cheng, MD, MPH, MMSc; C. Noel Bairey Merz, MD

Two-thirds of women who present with persistent symptoms and clinical signs of ischemia have no evidence of obstructive coronary artery disease (INOCA) on angiography.¹ Cardiac ischemia can be manifested by chest discomfort, shortness of breath, decreased exercise tolerance, and ST-segment or imaging abnormalities at rest or with stress. Although women with a clinical presentation suggesting ischemic heart disease are often reassured after having a "normal" angiogram that their symptoms are not likely cardiac in etiology, 1 in 13 of these women die from a cardiac cause within 10 years of the angiographic evaluation,² and the most frequent adverse cardiac event is hospitalization for heart failure with preserved ejection fraction with an observed 10-fold higher rate compared with asymptomatic women (3.3% vs 0.3%).¹ For these women with INOCA, clinicians should consider the important, yet often overlooked, diagnosis of coronary microvascular dysfunction (CMD)—a small vessel disorder that confers an adverse prognosis in women for which there are available and continuously evolving diagnostic and treatment strategies.

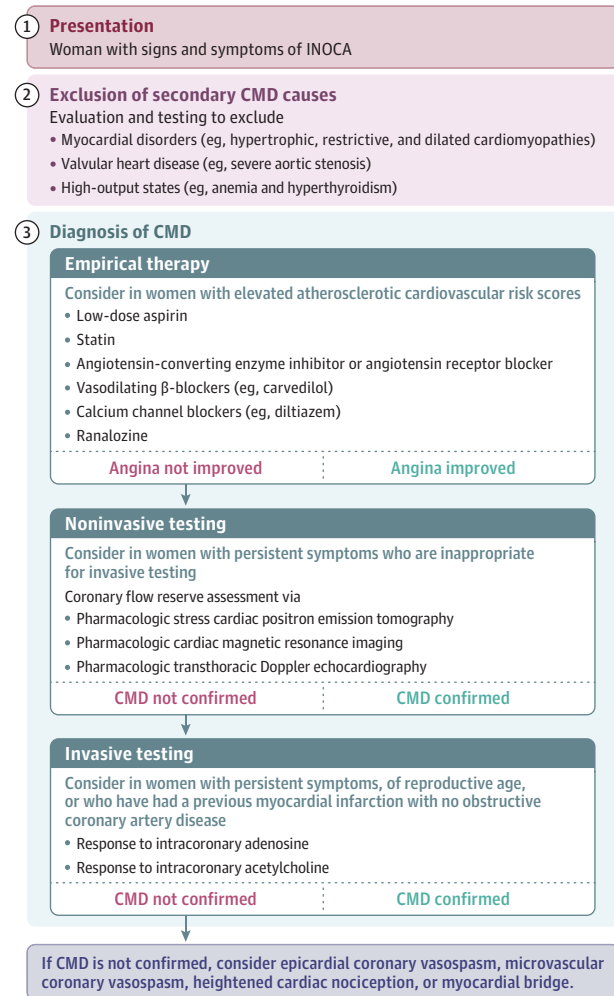
Diagnosis

A stepwise approach to treating a woman with possible CMD is summarized in the **Figure**. This approach is derived from expert consensus³ and has not been rigorously tested. The presence of secondary CMD due to myocardial disorders should be excluded. A CMD evaluation should be considered for individuals with the following clinical features: subjective report of symptoms consistent with ischemia; objective evidence of myocardial ischemia based on diagnostic tests of low functional capacity, dynamic abnormalities (such as exercise-induced angina or ST-segment electrocardiographic response), reversible abnormalities on noninvasive stress testing, or any acute coronary syndrome; and no obstructive coronary artery disease (CAD) found on invasive or noninvasive coronary angiography. Most women with CMD also have traditional cardiovascular risk factors, such as hypertension, hyperlipidemia, or a family history of premature coronary artery disease, and evidence of nonobstructive coronary atherosclerosis.¹ Presence of autoimmune disorders, history of cancer, and history of adverse pregnancy outcomes may also contribute to CMD. A diagnosis of CMD can be established by several strategies, including a trial of empirical therapy, noninvasive diagnostics, or invasive diagnostics (**Figure**).

Response to Empirical Therapy

Most women older than 65 years who undergo clinically indicated coronary angiography for INOCA have several risk factors and elevated atherosclerotic cardiovascular disease risk scores.⁴ For these women with no obstructive CAD, empirical therapy may be initiated to assess angina response to treatment. Optimal medical therapy includes a statin and low dose of aspirin based on stable ischemic heart disease guidelines.⁵ For individuals who are hyperten-

Figure. Proposed Approach for the Diagnosis of Coronary Microvascular Dysfunction (CMD) in Women With Ischemia With No Obstructive Coronary Artery Disease (INOCA)



sive, angiotensin-converting enzyme (ACE) inhibitor or angiotensin receptor blocker (ARB) agents are preferred for antianginal therapy, given that studies have demonstrated that they improve endothelial dysfunction and coronary flow reserve (CFR).¹ Other antianginal/anti-ischemic agents can be added, such as vasodilating β -blockers and nondihydropyridine or dihydropyridine calcium channel blockers and ranolazine.¹ Symptomatic improvement in response to empirical therapy may be sufficient for establishing a CMD diagnosis in patients with traditional risk factors.

Noninvasive Diagnostics

Traditional noninvasive diagnostic testing can include exercise electrocardiogram, stress echocardiography, and single-photon

emission computed tomography; however, these modalities have low sensitivity and moderate specificity for diagnosing CMD.¹ If a diagnosis of CMD is not considered, ST-segment abnormalities and anterior or apical perfusion defects may be incorrectly dismissed as false-positive findings or attributed to breast attenuation artifact in women with no obstructive CAD. For women with indeterminate or negative results for CMD who have persistent symptoms, did not respond to empirical therapy, and are not suitable for invasive testing, advanced noninvasive imaging modalities should be considered for the evaluation of abnormal CFR consistent with CMD; these modalities include pharmacologic stress cardiac positron emission tomography, cardiac magnetic resonance imaging, and transthoracic Doppler echocardiography.^{1,6,7} Importantly, while the noninvasive stress perfusion tests are able to measure CFR, which has prognostic implications and can guide medical management,¹ the noninvasive diagnostic tests are unable to identify an abnormal coronary vasodilation or constriction pathway for directing therapy. For this reason, and for high-risk patients, invasive diagnostic testing can be considered.

Invasive Diagnostics

The indications for invasive functional angiography testing include (1) lack of diagnosis for the cause of persistent chest pain after multiple prior medical encounters, (2) lack of symptom responsiveness to empirical therapy, or (3) uncertainty regarding utility of medical therapy for a symptomatic woman of reproductive age. The cardiovascular risks of INOCA and CMD are higher than the procedural risks of invasive functional angiography.³ Patients who have had a prior myocardial infarction with no obstructive CAD are at particularly high risk for adverse events; thus, invasive functional angiography testing may be the preferred initial step for such individuals, given its potential to identify the abnormal coronary pathways.¹ In particular, the benefits of invasive testing include the ability to identify the presence of specific vasodilation and vasoconstriction abnormalities, which allows for tailoring therapies.

Treatment Strategies

Given the lack of clinical outcome trials to date, practice guidelines do not currently address how to best treat women with INOCA and CMD. Previous clinical trials, which provided the existing evidence base for guidelines on secondary prevention for ischemic heart disease, did not typically stratify patients based on coronary angiography findings; thus, female and male patients with INOCA and CMD were included and not differentiated.⁵ In the absence of more specific evidence available at present, it is reasonable for current therapeutic approaches to involve secondary prevention measures, including optimal medical therapy and therapeutic lifestyle change.¹

Pharmacologic Strategies

Management of cardiovascular risk factors includes control of dyslipidemia, diabetes, and hypertension, in addition to therapy with low-dose aspirin. ACE inhibitors have been shown to improve CFR, exercise tolerance, and angina symptoms.¹ Carvedilol improves endothelial function.¹ Patients with abnormal vasodilator reserve have improved symptoms, less nitrate usage, and improved exercise tolerance after being treated with verapamil or nifedipine.¹ Statins not only lower cholesterol, but they also improve CFR.¹ The use of nitrates may or may not improve patients' symptoms due to lack of smooth muscle in the microvasculature, and nitrate tolerance can be problematic with long-acting nitrates. Ranolazine improves symptoms in patients with low CFR.¹

Conclusions

The diagnosis of CMD should be considered in women with INOCA. The risk for adverse cardiac events is relatively high in patients with CMD, despite the absence of obstructive CAD. Therapeutic strategies can include optimal medical therapy of intensive statin, ACE inhibitors/ARB, low-dose aspirin, and therapeutic lifestyle change as outlined in ischemic heart disease guidelines. Prospective registries are investigating INOCA in women and men, and randomized clinical outcome trials are examining treatment strategies.

ARTICLE INFORMATION

Author Affiliations: Barbra Streisand Women's Heart Center, Smidt Heart Institute, Cedars-Sinai Medical Center, Los Angeles, California.

Corresponding Author: C. Noel Bairey Merz, MD, Barbra Streisand Women's Heart Center, Cedars-Sinai Smidt Heart Institute, 127 S San Vicente Blvd, #A3906, Los Angeles, CA 90048 (merz@cshs.org).

Published Online: November 18, 2019.
doi:10.1001/jama.2019.15736

Conflict of Interest Disclosures: Dr Bairey Merz reported receiving honoraria, consulting fees, and grants from various companies, societies, academic institutions, and federal agencies paid to Cedars-Sinai and serving on the board of directors for iRhythm. No other disclosures were reported.

Funding/Support: This work was supported by the Barbra Streisand Women's Heart Center and grants from the NIH.

Role of the Funder/Sponsor: The funder had no role in the preparation, review, or approval of the

manuscript and decision to submit the manuscript for publication.

Disclaimer: This work is solely the responsibility of the authors and does not necessarily represent the official views of the NIH.

Additional Contributions: We thank Elizabeth Kim, BA (Smidt Heart Institute, Cedars-Sinai Medical Center), for her assistance in formatting the figures.

REFERENCES

- Bairey Merz CN, Pepine CJ, Walsh MN, Fleg JL. Ischemia and no obstructive coronary artery disease (INOCA): developing evidence-based therapies and research agenda for the next decade. *Circulation*. 2017;135(11):1075-1092. doi:10.1161/CIRCULATIONAHA.116.024534
- Kenkre TS, Malhotra P, Johnson BD, et al. Ten-Year Mortality in the WISE Study (Women's Ischemia Syndrome Evaluation). *Circ Cardiovasc Qual Outcomes*. 2017;10(12):e003863. doi:10.1161/CIRCOUTCOMES.116.003863
- Ong P, Camici PG, Beltrame JF, et al. International standardization of diagnostic criteria

for microvascular angina. *Int J Cardiol*. 2018;250:16-20. doi:10.1016/j.ijcard.2017.08.068

4. Herscovici R, Sedlak T, Wei J, et al. Ischemia and no obstructive coronary artery disease (INOCA): what is the risk? *J Am Heart Assoc*. 2018;7(17):e008868. doi:10.1161/JAHA.118.008868

5. Fihn SD, Gardin JM, Abrams J, et al. 2012 ACCF/AHA/ACP/AATS/PCNA/SCAI/STS guideline for the diagnosis and management of patients with stable ischemic heart disease. *Circulation*. 2012;126(25):e354-e471.

6. Thomson LE, Wei J, Agarwal M, et al. Cardiac magnetic resonance myocardial perfusion reserve index is reduced in women with coronary microvascular dysfunction. *Circ Cardiovasc Imaging*. 2015;8(4):e002481. doi:10.1161/CIRCIMAGING.114.002481

7. Tamis-Holland JE, Jneid H, Reynolds HR, et al. Contemporary diagnosis and management of patients with myocardial infarction in the absence of obstructive coronary artery disease. *Circulation*. 2019;139(18):e891-e908. doi:10.1161/CIR.0000000000000670