

Simon R. Mucha, MD

Critical Care Medicine, Respiratory Institute, Cleveland Clinic; Clinical Instructor, Cleveland Clinic Lerner College of Medicine of Case Western Reserve University, Cleveland, OH

Siddharth Dugar, MD

Pulmonary Medicine, Cleveland Clinic; Clinical Assistant Professor, Cleveland Clinic Lerner College of Medicine of Case Western Reserve University, Cleveland, OH

Keith McCrae, MD

Hematology and Medical Oncology, and Cellular and Molecular Medicine, Cleveland Clinic; Professor, Cleveland Clinic Lerner College of Medicine of Case Western Reserve University, Cleveland, OH

Douglas Joseph, DO

Cardiovascular Medicine, Cleveland Clinic; Assistant Professor, Cleveland Clinic Lerner College of Medicine of Case Western Reserve University, Cleveland, OH

John Bartholomew, MD

Cardiovascular Medicine, Cleveland Clinic; Professor, Cleveland Clinic Lerner College of Medicine of Case Western Reserve University, Cleveland, OH

Gretchen L. Sacha, PharmD, RPh, BCCCP

Inpatient Pharmacy, Cleveland Clinic

Michael Militello, PharmD, RPh, BCPS

Inpatient Pharmacy, Cleveland Clinic

Coagulopathy in COVID-19: Manifestations and management

ABSTRACT

Severe COVID-19 illness is associated with intense inflammation, leading to high rates of thrombotic complications that increase morbidity and mortality. Markedly elevated levels of D-dimer with normal fibrinogen levels are the hallmark laboratory findings of severe COVID-19–associated coagulopathy. Prophylaxis against venous thromboembolism is paramount for all hospitalized patients, with more aggressive prophylaxis and screening recommended for patients with D-dimer levels above 3.0 $\mu\text{g/mL}$. Point-of-care ultrasonography is the imaging method of choice for patients at high risk, as it entails minimal risk of exposing providers to the virus.

KEY POINTS

We recommend measuring D-dimer, fibrinogen, prothrombin time, international normalized ratio, and activated partial thromboplastin time every 48 hours in hospitalized patients with COVID-19.

Prophylaxis against venous thromboembolism is recommended for all COVID-19 patients on admission, using low-molecular-weight heparin, unfractionated heparin for those in renal failure, or fondaparinux for those with heparin-induced thrombocytopenia, even in the setting of thrombocytopenia as long as the platelet count is above $25 \times 10^9/\text{L}$.

Patients with D-dimer levels 3.0 $\mu\text{g/mL}$ or higher should undergo screening with point-of-care ultrasonography and receive more intensive prophylaxis.

COVID-19–ASSOCIATED COAGULOPATHY (CAC) and disseminated intravascular coagulation are common in COVID-19 and are associated with severe illness and death.^{1–3} Critically ill patients without other risk factors for thrombosis can experience various thrombotic events, including microvascular thrombosis, venous and pulmonary thromboembolism, and acute arterial thrombosis.⁴

This article discusses clinical manifestations of CAC, associated laboratory and histologic findings, recent evidence elucidating pathophysiologic mechanisms, and the way we manage it at Cleveland Clinic.

■ A HIGHLY THROMBOTIC STATE

The clinical presentation of CAC is that of a highly thrombotic state. Shared anecdotal experience from a variety of sources indicates that catheter-associated thrombosis and clotting of vascular access catheters are especially common problems. The need for catheter replacement and dialysis circuits that involve frequent interruption of continuous renal replacement therapy are other high-risk settings.

Two recent studies support the clinical impression that COVID-19 is highly thrombotic. Cui et al⁵ reported a 25% incidence of deep vein thrombosis in patients with severe coronavirus pneumonia. Klok et al⁴ found a 31% combined incidence of deep vein thrombosis, pulmonary embolism, and arterial thrombosis in critically ill patients with coronavirus. Of these events, 81% were pulmonary thromboembolic.

In Cleveland Clinic intensive care units, we are finding that point-of-care ultrasonography (POCUS) detects deep vein thrombosis at a rate of 25% to 30%, similar to rates

The clinical presentation of CAC is that of a highly prothrombotic state

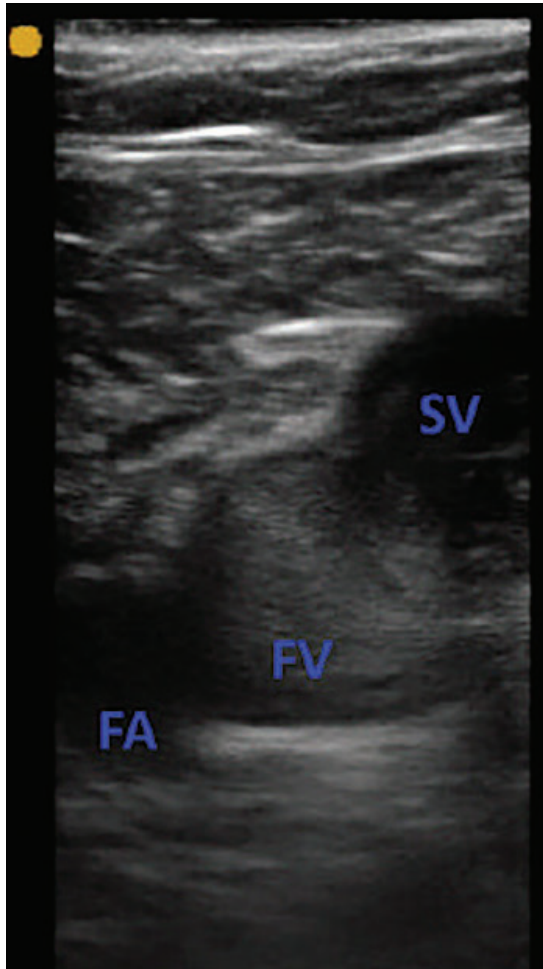


Figure 1. A short-axis view of the femoral vein (FV) and the femoral artery (FA) at the site of the saphenous vein (SV) inflow. Amorphous echogenicity in the femoral vein, greater than that of the adjacent femoral artery, is suggestive of slow venous flow. The vein was fully compressible, ruling out deep vein thrombosis at the site.

in these studies. Another frequent finding is “slow venous flow.” This pattern, described as amorphous echogenicity in major veins, has been associated with a higher subsequent risk of deep vein thrombosis (Figures 1–3).⁶

**LABORATORY FINDINGS:
ELEVATED D-DIMER**

The characteristic laboratory findings of CAC (ie, dramatically elevated levels of D-dimer and fibrin degradation products) indicate a highly thrombotic state with high fibrin turnover. How-

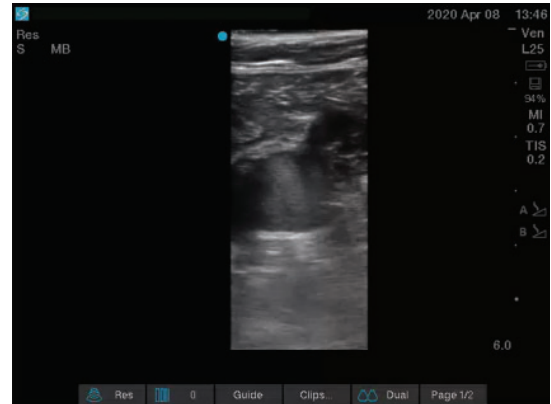

Figure 2. Another short-axis view of the femoral vein (center) and the femoral artery (bottom right) at the site of the saphenous vein inflow (top right). Swirling pattern of high echogenicity suggests low-flow state.

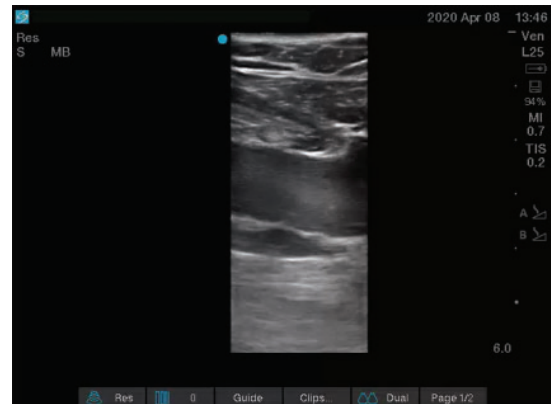

Figure 3. Long-axis view of the femoral vein, with spontaneous echogenicity and slow flow.

ever, other markers of disseminated intravascular coagulation remain relatively unchanged.⁷ The prothrombin time and activated partial thromboplastin time are only mildly prolonged, if at all, and platelet counts are usually normal or only mildly low ($100\text{--}150 \times 10^9/\text{L}$).^{8–10}

Elevated D-dimer levels on presentation with COVID-19 are associated with more severe disease. Levels of $0.5 \mu\text{g}/\text{mL}$ or higher were found in 59.6% of patients with severe disease vs 43.2% of those with mild disease.³ High levels also correlated with the need for intensive care¹¹ and with death.

In a multivariable regression analysis of 191 patients, Zhou et al¹ reported that the risk of death was more than 18 times higher (odds ratio 18.42, 95% confidence interval 2.64–128.55) for patients admitted with a D-dimer level greater than 1 µg/mL vs less than 0.5 µg/mL. Cui et al⁵ reported that D-dimer levels also correlated with risk of venous thromboembolism: a level of 3.0 µg/mL had a sensitivity of 70.0%, specificity of 96.7%, and positive predictive value of 87.5%. Maatman et al¹² reported that standard prophylaxis against venous thromboembolism failed in 29 of 109 patients in the intensive care unit, and of those in whom it failed, all had D-dimer levels greater than 3.0 µg/mL.

Other measures of coagulopathy also predictive

Other indicators of coagulopathy have also been studied in COVID-19 and found to be associated with increased risk.

Prothrombin time, activated partial thromboplastin time. Klok et al⁴ did not report D-dimer levels, but found coagulopathy (ie, prolongation of prothrombin time of > 3 seconds or of activated thromboplastin time > 5 seconds) to be an independent risk factor for thrombosis.

Antiphospholipid antibodies. Zhang et al¹³ reported that 3 patients with CAC and lower-extremity ischemia had antiphospholipid antibodies (anticardiolipin immunoglobulin A [IgA], anti-beta-2 glycoprotein 1 IgA and IgG) but not lupus anticoagulant. Helms et al,¹⁴ in a multicenter study of 150 patients with COVID-19 in intensive care units in France, found a remarkably high rate of positivity for lupus anticoagulant: 50 of 57 patients (87.7%) among those tested for further evaluation for an elevated activated partial thromboplastin time.

Disseminated intravascular coagulation score. Tang et al¹⁰ found that progression of coagulopathy to overt disseminated intravascular coagulation (defined by the International Society on Thrombosis and Haemostasis as a disseminated intravascular coagulation score ≥ 5 points; the score is based on platelet count, D-dimer level, fibrinogen level, and prolongation of the prothrombin time) predicted a poor prognosis, occurring in 71.4% of all nonsurvivors vs 0.6% of survivors.

Progressive consumptive coagulopathy. Declining levels of antithrombin III, a rise in prothrombin time and activated partial thromboplastin time, and dramatic further increase of D-dimer (> 15.0 µg/mL) appear to indicate severe and progressive disease, developing late in the disease course (day 10 to 14) of nonsurvivors. Fibrinogen levels, which are elevated in the initial phase, drop late in the course of disease in nonsurvivors and may signal impending death.¹⁰

Low platelet count. Lippi et al,⁸ in a meta-analysis of 9 studies with 1,779 patients with COVID-19, examined thrombocytopenia as a marker of disease severity. Thrombocytopenia at presentation was associated with an increased risk of severe disease and death, with a weighted mean difference of $31 \times 10^9/L$ in the platelet count between those with severe and nonsevere disease. The authors noted great heterogeneity among studies, with reported rates of thrombocytopenia in severe disease ranging from 4% to 57.7%.

SEVERE LUNG DAMAGE FROM INFLAMMATION, THROMBOSIS

Histopathologic studies reveal diffuse alveolar damage with profound inflammation, thrombosis, and thrombotic microangiopathy of small vessels and capillaries of the lung. Also noted have been megakaryocytes within pulmonary capillaries with nuclear hyperchromasia and atypia, as well as neutrophils partially degenerated and entrapped in fibers (suggesting neutrophil extracellular traps).¹⁵ An autopsy series of 11 patients showed thrombosis of small and mid-sized pulmonary arteries in all patients.¹⁶

Endothelial cell injury and diffuse microvascular thrombosis suggestive of thrombotic microangiopathy have also been reported in extrapulmonary organs, which may explain the acute onset of multiorgan failure without an otherwise obvious etiology.¹⁷

PATHOPHYSIOLOGY: INFLAMMATION PROMOTES THROMBOSIS

CAC is likely multifactorial, and patients with COVID-19 share many of the classic risk factors for venous thromboembolism seen in adult respiratory distress syndrome from other causes, such as immobility, large vascular-ac-

Elevated D-dimer levels on presentation correlate with disease severity

cess catheters, and systemic inflammation.

The hallmark of COVID-19 is profound inflammation, described as “cytokine storm,” characterized by high levels of interleukin 1 (IL-1), IL-6, tumor necrosis factor, and other inflammatory cytokines.¹¹ Inflammation promotes thrombosis through various mechanisms, including activation of endothelial cells, platelets, monocytes, and the tissue factor-factor VIIa pathway, and by altering fibrinolysis and natural anticoagulant pathways (eg, through changes in levels of thrombomodulin, proteins C and S, and tissue-factor-pathway inhibitor).^{18,19} Intense inflammation with thrombosis of pulmonary vessels is also seen in adult respiratory distress syndrome of other etiologies.²⁰ It remains to be seen if these findings represent a distinct phenotype unique to COVID-19 or are a general indicator of the severity of inflammation with COVID-19.

Serum proteomic profiling of patients with severe acute respiratory syndrome (SARS) identified an N-terminal fragment of complement C3C-alpha (a central component of the complement pathway) as a sensitive biomarker of early SARS.²¹ Murine models of SARS and Middle East respiratory syndrome (MERS) have shown that complement activation is a major contributor to lung injury and other organ failure. Complement inhibition in these models reduced organ damage and inflammation.^{22,23} Complement inhibition has been suggested as a treatment for COVID-19, but clinical data are not yet available.²⁴

One mechanism of microvascular thrombosis that may be specific to COVID-19 is the virus’s affinity for angiotensin-converting enzyme 2, which is expressed on alveolar epithelial type II cells and various extrapulmonary tissues, including endothelial cells. Endothelial cell activation may be a unique mechanism of COVID-19-mediated microvascular injury, thrombosis, and subsequent multisystem organ failure.^{25,26}

The rate of 87.7% positivity for lupus anticoagulant in patients with COVID-19 reported by Helms et al¹⁴ is striking and needs to be verified, but it supports the idea that endothelial injury is a key mechanism of multiorgan failure and coagulopathy in this disease. The “two-hit” model of thrombosis associated with antiphospholipid syndrome proposes that af-

ter a first-hit injury to the endothelium, antiphospholipid antibodies potentiate thrombus formation as a second hit.²⁷ Activation of the contact system due to increased vascular permeability and thrombotic microangiopathy warrant further exploration.²⁸

■ OUR MANAGEMENT APPROACH

Currently, CAC is managed largely on the basis of case reports and anecdotal experience; controlled studies are urgently needed to better guide care. Management strategies vary greatly among institutions and are likely to change as we learn more about this novel disease.

The approach outlined here describes the Cleveland Clinic consensus based on available information. It tries to balance the risk and benefits of empiric therapy, while minimizing the use of resources (eg, personal protective equipment) and exposure of caregivers to COVID-19.

Monitor D-dimer, fibrinogen, prothrombin time, activated partial thromboplastin time

In view of the characteristic laboratory findings of CAC described above, we monitor D-dimer, fibrinogen, prothrombin time-international normalized ratio, and activated partial thromboplastin time every 48 hours. We define a D-dimer level of at least 6 times the upper limit of normal (3.0 µg/mL fibrinogen equivalent units [FEU]) as high risk.^{5,10}

Because antiphospholipid antibodies, including lupus anticoagulant, have been reported in COVID-19, we recommend testing for these if the activated partial thromboplastin time is spontaneously elevated, and we prefer the use of anti-Xa assays to monitor anticoagulation. Anti-Xa assays however, may be affected by high levels of bilirubin (> 6.6 mg/dL) or triglycerides (> 360 mg/dL),²⁹ which are often elevated in patients with COVID-19 and cytokine storm. Triglyceride levels should therefore be monitored routinely and considered as a possible source of error in patients on anticoagulation who are difficult to maintain within the therapeutic target range.

A hypercoagulable pattern on viscoelastic testing (thromboelastography or rotational thromboelastometry), with faster time to clot formation, rapid clot propagation, and increased clot strength, has been described in several publications.^{12,30} However, no evidence

Inflammation promotes thrombosis through various mechanisms

exists on how to best use this information to guide therapy. In line with current guidance from the American Society of Hematology and the International Society on Thrombosis and Haemostasis, we do not routinely use viscoelastic testing to assess hypercoagulability.³¹

Imaging: Use POCUS

To limit caregiver exposure, we minimize formal bedside vascular studies and sending the patient out of the intensive care unit for computed tomographic angiography. We rely heavily on POCUS to assess for evidence of venous thromboembolism. This is in line with recent National Institutes of Health guidance,^{32,33} which cites a lack of evidence supporting routine screening examinations but highlights the value of POCUS in the hands of experienced clinicians. POCUS should be bundled with other care (for example, ultrasonography-guided vascular access) to minimize the use of personal protective equipment and caregiver exposure to COVID-19.

Patients at high risk (D-dimer > 3.0 µg/mL FEU) are assessed for deep vein thrombosis using a 3-point compression POCUS examination of both lower extremities. A POCUS deep vein thrombosis examination and echocardiography are also recommended for any patient with sudden cardiopulmonary decline that cannot be explained by an alternative etiology.

A positive POCUS examination for deep vein thrombosis is highly specific and does not need to be confirmed by formal vascular ultrasonography.³⁴ On the other hand, given the high incidence of pulmonary embolism described, confirmatory studies (ie, formal vascular ultrasonography or computed tomographic angiography) are warranted if the patient has contraindications to empiric anticoagulation and the clinical suspicion of venous thromboembolism is high despite negative POCUS, or if POCUS is not available.

Prophylactic heparin for most

Specific data on the management of CAC are extremely limited, but heparin seems to be the obvious response to such a hypercoagulable process.

In addition to its antithrombotic effect, heparin may have anti-inflammatory, anti-complement,³⁵ and direct antiviral effects that may be beneficial in COVID-19. Heparin

inhibits neutrophil activation, binds inflammatory cytokines, and reduces endothelial activation.³⁶ Experimental models have also shown that heparin directly binds to SARS-CoV spike protein, the viral anchor site, thereby blocking viral entry into the cell.³⁷ While promising, these effects have yet to be demonstrated clinically.

Tang et al³⁸ reported on 449 patients with severe COVID-19 in whom the overall mortality rate was no different (29.7% vs 30.3%, $P = .910$) between those who received heparin (94 patients on low-molecular-weight heparin, 5 patients on unfractionated heparin; prophylactic doses) and those who did not. But among patients with a D-dimer level of more than 6 times the upper limit of normal (> 3.0 µg/mL), heparin recipients had a significantly lower mortality rate than nonrecipients (32.8% vs 52.4%, $P = .017$). The authors concluded that heparin lowers mortality rates in patients with severe COVID-19 and cited a Chinese consensus statement recommending anticoagulation in severe COVID-19. We emphasize that this study retrospectively compared heparin prophylaxis with no prophylaxis.

Full anticoagulation for some?

Some evidence indicates that elevated D-dimer levels may predict higher risk of venous thromboembolism despite standard prophylaxis. In a study of 240 critically ill patients with COVID-19, Maatman et al¹² reported a 28% rate of venous thromboembolism in patients receiving standard prophylaxis. Elevated D-dimer (> 2.6 µg/mL) predicted venous thromboembolism with a sensitivity of 89.7%. The authors concluded that standard prophylactic anticoagulant doses may be insufficient to prevent venous thromboembolism in high-risk patients.

Paranjpe et al,³⁹ in an observational report of 2,773 patients with COVID-19 admitted to a single institution in New York, found that those treated with full anticoagulation (786 patients, 28%) had a similar mortality rate (22.5%) vs those treated with prophylaxis only (22.8%). But among mechanically ventilated patients, in-hospital mortality was 29.1% for those treated with anticoagulation vs 62.7% for patients who did not receive anticoagulation. Despite this dramatic reduction of mortality, the authors advise caution in ap-

A late drop in fibrinogen levels may signal impending death

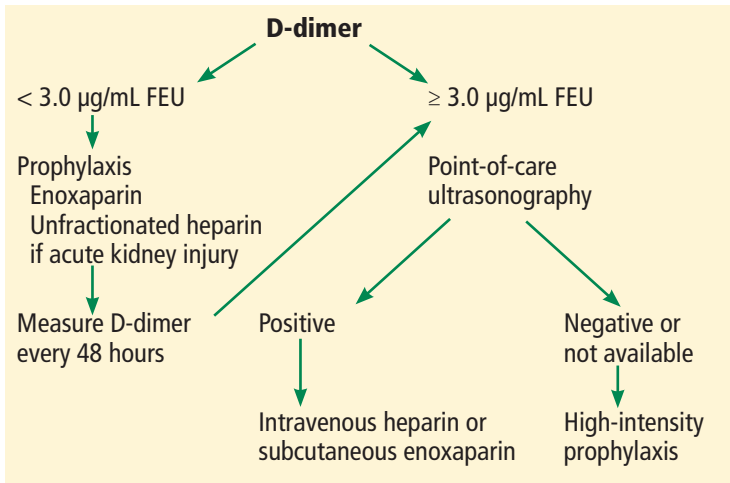


Figure 4. Algorithm for preventing and treating COVID-19-associated coagulopathy.

FEU = fibrinogen equivalent units

A positive POCUS for DVT is highly specific and does not require confirmation

plying these findings, given the serious limitations of the report, ie, its observational nature and lack of information on illness severity and indications for anticoagulation.

Taken together, this limited evidence confirms that prophylaxis against venous thromboembolism in critically ill COVID-19 patients is associated with improved outcomes, and there may be a role for full anticoagulation.

Given the limitations of the studies thus far, it remains unclear if higher prophylactic doses or full anticoagulation offer a benefit beyond standard prophylactic dosing, and which patients may benefit without suffering more bleeding complications.

Thrombolysis has also been suggested for patients whose condition deteriorates despite anticoagulation. Three patients with persistent severe hypoxia and markedly elevated D-dimer showed improvement in oxygenation after being given low-dose tissue plasminogen activator. But despite initial improvement and no reported adverse effects, the ultimate outcome was poor: the improvement was long-lasting in 1 patient but transient in the other 2, and 1 patient died.⁴⁰

Recommendations

Given this lack of evidence, the National Institutes of Health, American Society of Hematology, and International Society on Thrombosis and Haemostasis currently do not recommend treatment beyond standard prophylaxis except for an established indication. The two societies

strongly recommend prophylaxis against deep vein thrombosis in all patients on admission, using low-molecular-weight heparin (or unfractionated heparin in those with renal failure, or fondaparinux in those with heparin-induced thrombocytopenia). They stress that prophylaxis should be continued even in the setting of thrombocytopenia so long as the platelet count is higher than $25 \times 10^9/L$.^{31,41}

Our current approach is based on POCUS screening for venous thromboembolism and intensified prophylaxis in high-risk patients (Figure 4, Table 1). We divide patients into 3 categories:

- **Category 1:** D-dimer less than 3.0 µg/mL FEU and no evidence of venous thromboembolism. Patients receive standard prophylaxis and are monitored using serial D-dimer testing.
- **Category 2:** D-dimer 3.0 µg/mL FEU or higher, POCUS-negative. Patients receive intensified deep vein thrombosis prophylaxis.
- **Category 3:** Confirmed thrombosis. Patients receive full anticoagulation.

If the clinical suspicion of venous thromboembolism is high and the patient has no contraindication to anticoagulation, full anticoagulation should be initiated empirically if POCUS or confirmatory tests are not immediately available.

Continuous renal replacement therapy

Given the high rate of clotting in dialysis circuits, all patients on continuous renal replacement therapy receive unfractionated heparin at a rate of 500 U per hour. If ongoing clotting is observed, we increase systemic heparin to bring the activated partial thromboplastin time into the target range according to an acute coronary syndrome nomogram. The target activated partial thromboplastin time is 49 to 67 seconds, and the goal anti-factor Xa level is 0.2 to 0.5 IU/mL, but these may be adjusted if clotting continues despite systemic heparin.

Duration of anticoagulation

Anticoagulation should be continued for 6 weeks for catheter-associated thrombosis and for at least 3 months for venous thromboembolism. Convalescent patients with persistently elevated D-dimer (greater than twice the upper limit of normal) may benefit from extended prophylaxis or treatment.^{42,43}

TABLE 1

Cleveland Clinic approach to anticoagulation prophylaxis and management in COVID-19

	Category 1 D-dimer < 3.0 µg/mL FEU Standard prophylaxis	Category 2 D-dimer ≥ 3.0 µg/mL FEU High-intensity prophylaxis	Category 3 Confirmed VTE Full anticoagulation
Standard	Enoxaparin 40 mg subcutaneously every 24 hours	Enoxaparin 40 mg subcutaneously every 12 hours	IV heparin per DVT/PE nomogram or enoxaparin 1 mg/kg subcutaneously every 12 hours
Renal failure	CrCl 10–30 mL/min: Enoxaparin 30 mg subcutaneously every 24 hours CrCl < 10 mL/min or AKI^a: Unfractionated heparin 5,000 U subcutaneously every 12 hours CRRT: Unfractionated heparin 500 U/hour through circuit Circuit clotting: IV heparin per ACS nomogram ^a	CrCl < 30 mL/min or AKI: Enoxaparin 40 mg subcutaneously every 24 hours CrCl < 10 mL/min or AKI^a: Unfractionated heparin 7,500 U subcutaneously every 12 hours CRRT: Unfractionated heparin 500 U/hour through circuit Circuit clotting: IV heparin per ACS nomogram ^a	IV heparin per DVT/VTE nomogram
Obesity			
Standard	> 100 kg: Enoxaparin 40 mg subcutaneously every 12 hours > 120 kg: Enoxaparin 60 mg subcutaneously every 12 hours	> 100 kg: Enoxaparin 60 mg subcutaneously every 12 hours > 120 kg: Enoxaparin 80 mg subcutaneously every 12 hours	IV heparin per DVT/PE nomogram or Enoxaparin 1 mg/kg subcutaneously every 12 hours, up to 150 mg Above 150 kg use unfractionated heparin
Renal failure	≤ 120 kg: 7,500 U every 12 hours > 120 kg: 10,000 U every 12 hours CRRT: 500 U/h through circuit Circuit clotting: IV heparin per ACS nomogram ^a	≤ 120 kg: 7,500 U every 8 hours > 120 kg: 10,000 U every 8 hours CRRT: 500 U/h through circuit Circuit clotting: IV heparin per ACS nomogram ^a	IV heparin per DVT/PE nomogram
CrCl < 30 mL/min or AKI ^b			

^aIV heparin ACS nomogram: initial dose 60-U/kg bolus, then 12 U/kg/hour; target aPTT 49–67 seconds; target heparin anti-Xa 0.2–0.5 units/mL.

^bAKI definition: doubling of creatinine in 48 hours or anuria.

ACS = acute coronary syndrome; AKI = acute kidney injury; aPTT = activated partial thromboplastin time; CrCl = creatinine clearance; CRRT = continuous renal replacement therapy; DVT = deep vein thrombosis; FEU = fibrinogen equivalent units; IV = intravenous; PE = pulmonary embolism; VTE = venous thromboembolism

REFERENCES

- Zhou F, Yu T, Du R, et al. Clinical course and risk factors for mortality of adult inpatients with COVID-19 in Wuhan, China: a retrospective cohort study. *Lancet* 2020; 395(10229):1054–1062. doi:10.1016/S0140-6736(20)30566-3
- Wu C, Chen X, Cai Y, et al. Risk factors associated with acute respiratory distress syndrome and death in patients with coronavirus disease 2019 pneumonia in Wuhan, China. *JAMA Intern Med* 2020; Mar 13;e200994. doi:10.1001/jamainternmed.2020.0994
- Guan WJ, Ni ZY, Hu Y, et al; China Medical Treatment Expert Group for Covid-19. Clinical characteristics of coronavirus disease 2019 in China. *N Engl J Med*

- J Med 2020; 382(18):1708–1720. doi:10.1056/NEJMoa2002032
4. **Klok FA, Kruij MJ, van der Meer NJ, et al.** Incidence of thrombotic complications in critically ill ICU patients with COVID-19. *Thromb Res* 2020; 191:145–147. doi:10.1016/j.thromres.2020.04.013
 5. **Cui S, Chen S, Li X, Liu S, Wang F.** Prevalence of venous thromboembolism in patients with severe novel coronavirus pneumonia. *J Thromb Haemost* 2020; 18(6):1421–1424. doi:10.1111/jth.14830
 6. **Jensen CT, Chahin A, Amin VD, et al.** Qualitative slow blood flow in lower extremity deep veins on Doppler sonography: quantitative assessment and preliminary evaluation of correlation with subsequent deep venous thrombosis development in a tertiary care oncology center. *J Ultrasound Med* 2017; 36(9):1867–1874. doi:10.1002/jum.14220
 7. **Yin S, Huang M, Li D, Tang N.** Difference of coagulation features between severe pneumonia induced by SARS-CoV2 and non-SARS-CoV2. *J Thromb Thrombolysis* 2020; Apr 3:1–4. doi:10.1007/s11239-020-02105-8
 8. **Lippi G, Plebani M, Henry BM.** Thrombocytopenia is associated with severe coronavirus disease 2019 (COVID-19) infections: a meta-analysis. *Clin Chim Acta* 2020; 506:145–148. doi:10.1016/j.cca.2020.03.022
 9. **Han H, Yang L, Liu R, et al.** Prominent changes in blood coagulation of patients with SARS-CoV-2 infection. *Clin Chem Lab Med* 2020; 58(7):1116–1120. doi:10.1515/cclm-2020-0188
 10. **Tang N, Li D, Wang X, Sun Z.** Abnormal coagulation parameters are associated with poor prognosis in patients with novel coronavirus pneumonia. *J Thromb Haemost* 2020; 18(4):844–847. doi:10.1111/jth.14768
 11. **Huang C, Wang Y, Li X, et al.** Clinical features of patients infected with 2019 novel coronavirus in Wuhan, China. *Lancet* 2020; 395(10223):497–506. doi:10.1016/S0140-6736(20)30183-5
 12. **Maatman TK, Jalali F, Feizpour C, et al.** Routine venous thromboembolism prophylaxis may be inadequate in the hypercoagulable state of severe coronavirus disease 2019. *Crit Care Med* 2020 May 27; 10.1097/CCM.0000000000004466. doi:10.1097/CCM.0000000000004466
 13. **Zhang Y, Xiao M, Zhang S, et al.** Coagulopathy and antiphospholipid antibodies in patients with COVID-19. *N Engl J Med* 2020; 382(17):e38. doi:10.1056/NEJMc2007575
 14. **Helms J, Tacquard D, Severac F, et al.** High risk of thrombosis in patients in severe SARS-CoV-2 infection: a multicenter prospective cohort study. *Intensive Care Med* 2020; 46(6):1089–1098. doi:10.1007/s00134-020-06062-x
 15. **Fox SE, Akmatbekov A, Harbert JL, Li G, Brown JQ, Vander Heide RS.** Pulmonary and cardiac pathology in COVID-19: the first autopsy series from New Orleans. *MedRxiv* 2020; April 10. doi:10.1101/2020.04.06.20050575
 16. **Lax SF, Skok K, Zechner P, et al.** Pulmonary arterial thrombosis in COVID-19 with fatal outcome: results from a prospective, single-center, clinicopathologic case series. *Ann Intern Med* 2020 May 14:M20-2566. doi:10.7326/M20-2566
 17. **Zhang T, Sun LX, Feng RE.** Comparison of clinical and pathological features between severe acute respiratory syndrome and coronavirus disease 2019. *Zhonghua Jie He He Hu Xi Za Zhi* 2020; 43(6):496–502. Chinese. doi:10.3760/cma.j.cn112147-20200311-00312
 18. **Levi M, Scully M.** How I treat disseminated intravascular coagulation. *Blood* 2018; 131(8):845–854. doi:10.1182/blood-2017-10-804096
 19. **Engelmann B, Massberg S.** Thrombosis as an intravascular effector of innate immunity. *Nat Rev Immunol* 2013; 13(1):34–45. doi:10.1038/nri3345
 20. **Glas GJ, Van Der Sluijs KF, Schultz MJ, Hofstra JJ, Van Der Poll T, Levi M.** Bronchoalveolar hemostasis in lung injury and acute respiratory distress syndrome. *J Thromb Haemost* 2013; 11(1):17–25. doi:10.1111/jth.12047
 21. **Pang RT, Poon CT, Chan KC, et al.** Serum proteomic fingerprints of adult patients with severe acute respiratory syndrome. *Clin Chem* 2006; 52(3):421–429. doi:10.1373/clinchem.2005.061689
 22. **Gralinski LE, Sheahan TP, Morrison TE, et al.** Complement activation contributes to severe acute respiratory syndrome coronavirus pathogenesis. *mBio* 2018; 9(5). doi:10.1128/mBio.01753-18
 23. **Jiang Y, Zhao G, Song N, et al.** Blockade of the C5a-C5aR axis alleviates lung damage in hDPP4-transgenic mice infected with MERS-CoV. *Emerg Microbes Infect* 2018; 7(1):77. doi:10.1038/s41426-018-0063-8
 24. **Campbell CM, Kahwash R.** Will complement inhibition be the new target in treating COVID-19 related systemic thrombosis? *Circulation* 2020; 141(22):1739–1741. doi:10.1161/CIRCULATIONAHA.120.047419
 25. **Kuba K, Imai Y, Rao S, et al.** A crucial role of angiotensin converting enzyme 2 (ACE2) in SARS coronavirus-induced lung injury. *Nat Med* 2005; 11(8):875–879. doi:10.1038/nm1267
 26. **Zhang H, Penninger JM, Li Y, Zhong N, Slutsky A.** Angiotensin-converting enzyme 2 (ACE2) as a SARS-CoV-2 receptor: molecular mechanisms and potential therapeutic target. *Intensive Care Med* 2020; 46(4):586–590. doi:10.1007/s00134-020-05985-9
 27. **Giannakopoulos B, Krilis SA.** The pathogenesis of the antiphospholipid syndrome. *N Engl J Med* 2013; 368(11):1033–1044. doi:10.1056/NEJMra1112830
 28. **Shatzel JJ, DeLoughery EP, Lorenz CU, et al.** The contact activation system as a potential therapeutic target in patients with COVID-19. *Res Pract Thromb Haemost* 2020; 4(4):500–505. doi:10.1002/rth2.12349
 29. **Hutt Centeno E, Militello M, Gomes MP.** Anti-Xa assays: what is their role today in antithrombotic therapy? *Cleve Clin J Med* 2019; 86(6):417–425. doi:10.3949/ccjm.86a.18029
 30. **Ranucci M, Ballotta A, Di Dedda U, et al.** The procoagulant pattern of patients with COVID-19 acute respiratory distress syndrome. *J Thromb Haemost* 2020 Apr 17. doi:10.1111/jth.14854
 31. **Thachil J, Tang N, Gando S, et al.** ISTH interim guidance on recognition and management of coagulopathy in COVID-19. *J Thromb Haemost* 2020; 18(5):1023–1026. doi:10.1111/jth.14810
 32. **National Institutes of Health.** Antithrombotic therapy in patients with COVID-19. Accessed July 10, 2020. <https://www.covid19treatmentguidelines.nih.gov/antithrombotic-therapy/>
 33. **Moore LK, Tritschler T, Brosnahan S, et al.** Prevention, diagnosis, and treatment of VTE in patients with COVID-19. Chest guideline and expert panel report. *Chest* 2020 Jun 2. doi:10.1016/j.chest.2020.05.559
 34. **Pedraza García J, Valle Alonso J, Ceballos García P, Rico Rodríguez F, Aguayo López MÁ, Muñoz-Villanueva MDC.** Comparison of the accuracy of emergency department-performed point-of-care-ultrasound (POCUS) in the diagnosis of lower-extremity deep vein thrombosis. *J Emerg Med* 2018; 54(5):656–664. doi:10.1016/j.jemermed.2017.12.020
 35. **Girardi G, Redecha P, Salmon JE.** Heparin prevents antiphospholipid antibody-induced fetal loss by inhibiting complement activation. *Nat Med* 2004; 10(11):1222–1226. doi:10.1038/nm1121
 36. **Poterucha TJ, Libby P, Goldhaber SZ.** More than an anticoagulant: do heparins have direct anti-inflammatory effects? *Thromb Haemost* 2017; 117(3):437–444. doi:10.1160/TH16-08-0620
 37. **Lang J, Yang N, Deng J, et al.** Inhibition of SARS pseudovirus cell entry by lactoferrin binding to heparan sulfate proteoglycans. *PLoS One* 2011; 6(8):e23710. doi:10.1371/journal.pone.00223710
 38. **Tang N, Bai H, Chen X, Gong J, Li D, Sun Z.** Anticoagulant treatment is associated with decreased mortality in severe coronavirus disease 2019 patients with coagulopathy. *J Thromb Haemost* 2020; Mar 27. doi:10.1111/jth.14817
 39. **Paranjpe I, Fuster V, Lala A, et al.** Association of treatment dose anticoagulation with in-hospital survival among hospitalized patients with COVID-19. *J Am Coll Cardiol* 2020 May 5; S0735-1097(20)35218-9. doi:10.1016/j.jacc.2020.05.001
 40. **Wang J, Hajizadeh N, Moore EE, et al.** Tissue plasminogen activator (tPA) treatment for COVID-19 associated acute respiratory distress syndrome (ARDS): a case series. *J Thromb Haemost* 2020; Apr 8; 10.1111/jth.14828. doi:10.1111/jth.14828
 41. **American Society of Hematology.** COVID-19 resources. COVID-19 and coagulopathy: frequently asked questions. <https://www.hematology.org/covid-19/covid-19-and-coagulopathy>. Accessed June 18, 2020.
 42. **Palareti G, Cosmi B, Legnani C, et al; DULCIS (D-dimer and Ultrasonography in Combination Italian Study) Investigators.** D-dimer to guide the duration of anticoagulation in patients with venous thromboembolism: a management study. *Blood* 2014; 124(2):196–203. doi:10.1182/blood-2014-01-548065
 43. **Cohen AT, Harrington RA, Goldhaber SZ, et al; APEX Investigators.** Extended thromboprophylaxis with betrixaban in acutely ill medical patients. *N Engl J Med* 2016; 375(6):534–544. doi:10.1056/NEJMoa1601747

Address: John R. Bartholomew, MD, Cardiovascular Medicine, ST20, Cleveland Clinic, 9500 Euclid Avenue, Cleveland, OH 44195; bartho@ccf.org