

Teaching Rounds in Cardiac Electrophysiology

Mitral Isthmus Ablation

Is the Conduction Block Completed? The Importance of the Marshall Bundle Epicardial Connections

Yasushi Wakabayashi, MD; Takekuni Hayashi, MD; Jun Matsuda, MD;
Yoshitaka Sugawara, MD; Takeshi Mitsuhashi, MD, PhD; Hideo Fujita, MD, PhD;
Shin-ichi Momomura, MD, PhD

Case Presentation

A 66-year-old man underwent electrophysiological study and catheter ablation for persistent atrial fibrillation. At the beginning of the procedure, sinus rhythm was restored by internal cardioversion. Circumferential pulmonary vein isolation was performed, and the electric isolation of all 4 pulmonary veins was confirmed. Subsequently, linear ablation of a left atrial roof and the mitral isthmus (MI) was performed. The MI ablation was applied from the 4 o'clock direction of the mitral annulus (MA) to the left-side pulmonary vein bottoms, and further radiofrequency applications were delivered within the coronary sinus (CS) opposite of the endocardial MI line. We confirmed the complete conduction block of the roof line, and the activation sequence of the CS during the left atrial appendage (LAA) pacing was changed from distal to proximal (Figure 1A) to proximal to distal (Figure 1B) while the MI ablation was being performed. Furthermore, the conduction time from the distal CS electrodes (CS 1–2) to the LAA during CS 1 to 2 pacing was longer than the conduction time from the proximal CS electrodes (CS 7–8) to the LAA during CS 7 to 8 pacing after the MI ablation (Figure 1C and 1D). Was the conduction block of the MI completed?

See Editor's Perspective

Commentary

If complete MI block is achieved, counterclockwise activation around the MA will be observed during LAA pacing,¹ and the conduction time from the distal CS electrode to the LAA during distal CS pacing will be longer than the conduction time from the proximal CS electrode to the LAA during proximal CS pacing.² The present case fulfilled the above conditions, which indicated apparent bidirectional MI block. However, the LAA activation sequence during CS 1 to 2 pacing was different from the LAA activation sequence during CS 7 to 8 pacing (Figure 1C and 1D), which suggested 2 or more pathways for propagation from the CS to the LAA during CS pacing.

Because the complete conduction block of the roof line was confirmed, we suspected the presence of an epicardial

conduction pathway via a Marshall bundle (MB) bypassing the endocardial MI line and inserted a 2F octapolar electrode catheter (EPstar, Japan Lifeline Corp., Tokyo, Japan) into the vein of Marshall (VOM; Figure 2A and 2B). The activation sequence in the VOM was distal to proximal during LAA pacing (Figure 3A), and we suspected the presence of electric conduction from the LAA to the VOM via the distal MB–LA connection.

Radiofrequency catheter ablation was applied at the ridge defined as the area between the left-side pulmonary vein and the LAA (Figure 2B and 2C). The activation sequence of the VOM during the LAA pacing was thereby changed to proximal to distal (Figure 3B), which indicated the presence of a distal MB–LA connection that had been disconnected by the ridge ablation. The single potentials shown in the ablation catheter 1 to 2 changed to the widely split double potentials. Furthermore, the conduction time from the LAA to CS 1 to 2 during the LAA pacing was prolonged, whereas the conduction time from the LAA to CS 7 to 8 was not prolonged. In addition, the intracardiac electrogram polarity of CS 7 to 8 was identical before and after the ridge ablation (Figure 3A and 3B). These observations suggested that the conduction pathway from the LAA to CS 1 to 2 during LAA pacing was changed from conduction via the MB–LA connection pathway to the MA, whereas the conduction pathway to CS 7 to 8 was not changed from the MA as a consequence of the ridge ablation (Figure 3C and 3D). The conduction time from CS 1 to 2 to the LAA during CS 1 to 2 pacing was also prolonged (Figure 4A), whereas the conduction time from CS 7 to 8 to the LAA during CS 7 to 8 pacing was not prolonged (Figure 4B) after the ridge ablation. The possible mechanism of these observations is presented in Figure 5. In addition, it should be noted that the activation sequence of the LAA during CS 1 to 2 pacing became equal to the activation sequence during CS 7 to 8 pacing after the ridge ablation (Figure 4), which indicated the presence of a single conduction pathway from the CS to the LAA during CS pacing (Figure 5C and 5D). The complete MI conduction block was ultimately achieved after a ridge ablation that disconnected the MB–LA connection.

Received April 9, 2015; accepted June 23, 2015.

From the Division of Cardiovascular Medicine, Saitama Medical Center, Jichi Medical University, Saitama City, Saitama, Japan.

Correspondence to Takekuni Hayashi, MD, Division of Cardiovascular Medicine, Saitama Medical Center, Jichi Medical University, 1-847 Amanuma, Omiya-ku, Saitama City, Saitama 330-8503, Japan. E-mail hayashi1979@yahoo.co.jp

(*Circ Arrhythm Electrophysiol*. 2016;9:e003049. DOI: 10.1161/CIRCEP.115.003049.)

© 2016 American Heart Association, Inc.

Circ Arrhythm Electrophysiol is available at <http://circep.ahajournals.org>

DOI: 10.1161/CIRCEP.115.003049

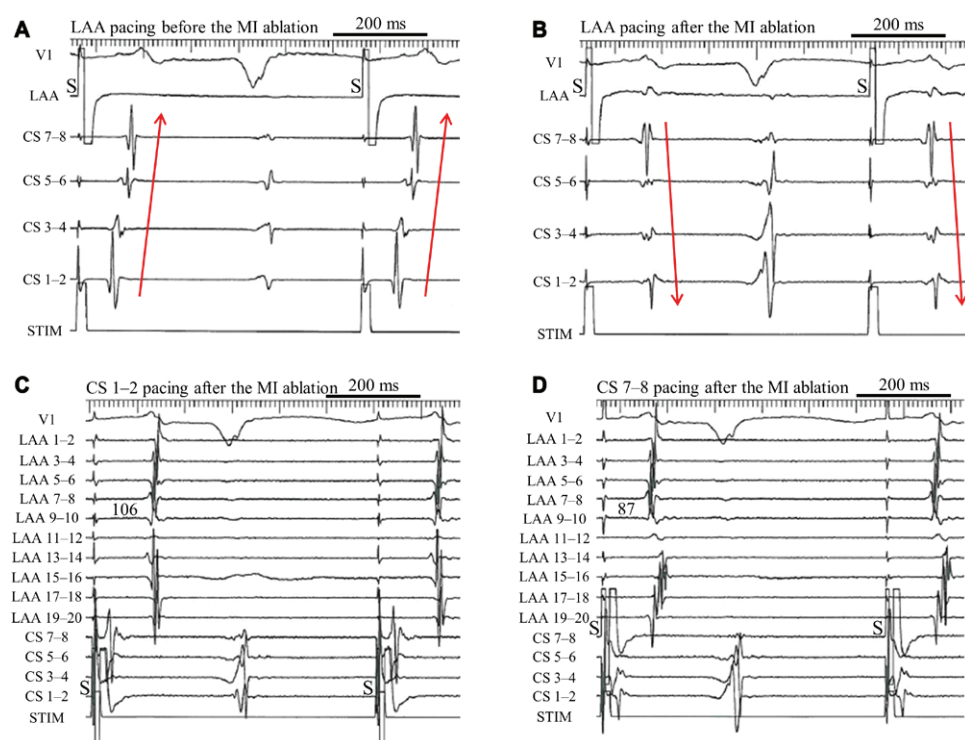


Figure 1. Intracardiac electrograms before and after the mitral isthmus (MI) ablation. **A**, Before the MI ablation, the activation sequence of the coronary sinus (CS) was distal to proximal. **B**, After the MI ablation, the activation sequence of the CS was changed to proximal to distal. **C**, After the MI ablation, the conduction time from CS 1 to 2 to the left atrial appendage (LAA) was 106 ms during CS 1 to 2 pacing. **D**, After the MI ablation, the conduction time from CS 7 to 8 to the LAA was 87 ms during CS 7 to 8 pacing. The conduction time from CS 1 to 2 to the LAA during CS 1 to 2 pacing was longer than the conduction time from CS 7 to 8 to the LAA during CS 7 to 8 pacing. In addition, the LAA activation sequence during CS 1 to 2 pacing differed from the LAA activation sequence during CS 7 to 8 pacing.

MI ablation is performed to prevent perimitral atrial tachycardia, which typically occurs after left atrial ablation for atrial fibrillation, and the MB has been reported to

be a part of the perimitral atrial tachycardia circuit.³ Briceño and Valderrábano⁴ reported a case with recurrent perimitral atrial tachycardia because of MB epicardial connections

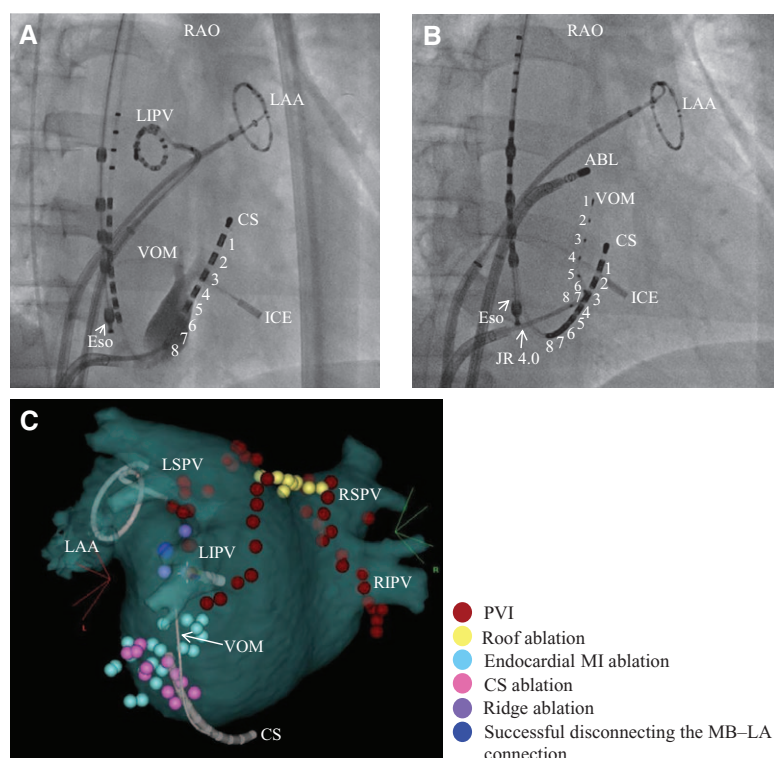


Figure 2. Catheter positions in fluoroscopy in the right anterior oblique (RAO) projection and 3-dimensional (3D) anatomic map of the left atrium. **A**, Fluoroscopic image shows the venography of the vein of Marshall (VOM). **B**, The 2F octapolar electrode catheter was positioned in the VOM using a 4F Judkins Right (JR) 4.0 guide catheter. At this point, the ablation catheter was positioned at the ridge. **C**, The 3D anatomic map shows the successful ablation site that was indicated by the blue dot. Radiofrequency catheter ablation was applied at this site and thereby successfully disconnected the Marshall bundle-left atrium (MB-LA) connection. ABL indicates ablation catheter; CS, coronary sinus; Eso, esophageal temperature monitoring catheter; ICE, intracardiac echocardiography catheter (SoundStar catheter, Biosense Webster Corp., Diamond Bar, CA); LAA, left atrial appendage; LIPV, left inferior pulmonary vein; LSPV, left superior pulmonary vein; MI, mitral isthmus; PVI, pulmonary vein isolation; RIPV, right inferior pulmonary vein; and RSPV, right superior pulmonary vein.

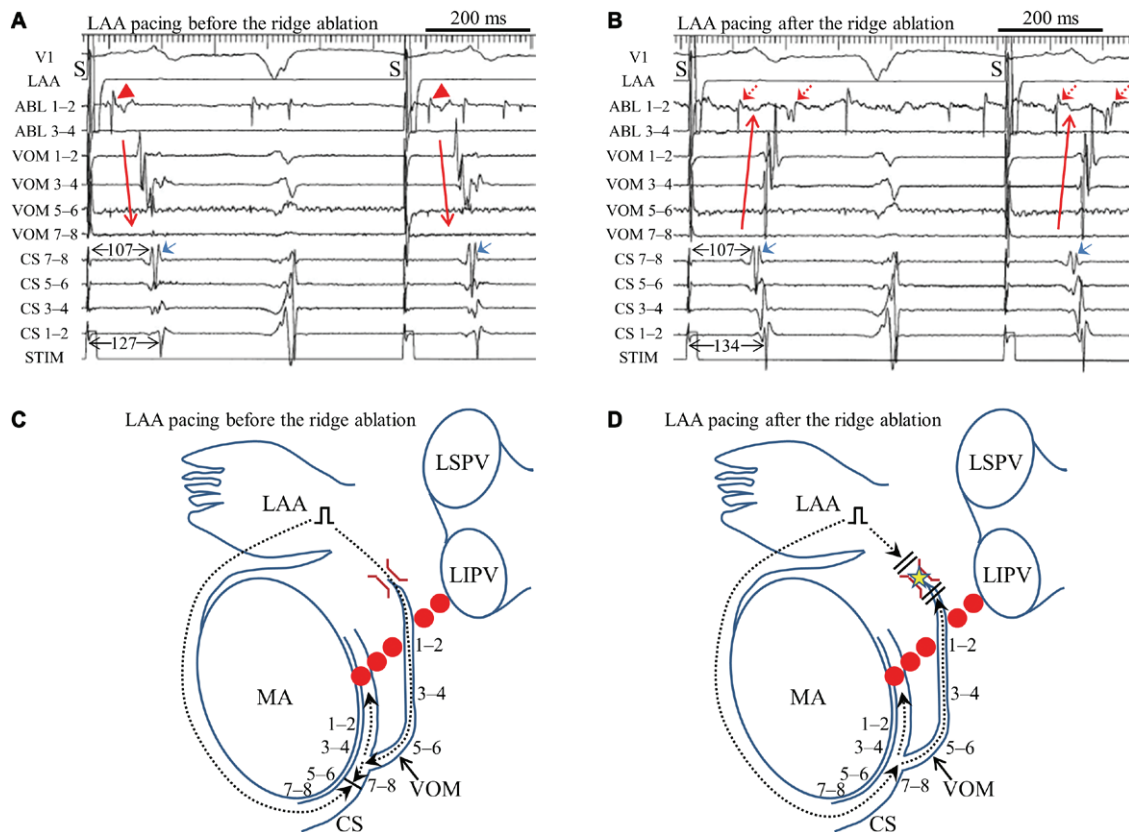


Figure 3. Intracardiac electrograms and schematic presentation before and after the ridge ablation. **A**, Before the ridge ablation, the activation sequence of the vein of Marshall (VOM) during the left atrial appendage (LAA) pacing was distal to proximal and the ablation catheter 1 to 2 showed single potentials (red arrowheads). **B**, After the ridge ablation, the activation sequence of the VOM changed to proximal to distal, and the ablation catheter 1 to 2 electrogram also changed to widely split double potentials (arrows with red dotted lines). The conduction time from the LAA to coronary sinus (CS) 1 to 2 during the LAA pacing was prolonged, even though the conduction time from the LAA to CS 7 to 8 during the LAA pacing was unchanged. In addition, the polarity of the CS 7 to 8 electrogram was not changed after the ridge ablation (blue arrow). **C**, Before the ridge ablation, the conduction pathway from the LAA to CS 1 to 2 proceeded via the Marshall bundle–left atrial (MB–LA) connection pathway, and the conduction pathway from the LAA to CS 7 to 8 proceeded via the mitral annulus (MA) during LAA pacing. The earliest CS activation site during LAA pacing was CS 7 to 8 in **A** of the current figure, which suggested that the wavefront of electric conduction proceeding via the MA reached the CS earlier than the wavefront proceeding via the MB–LA connection pathway. **D**, After the ridge ablation, the conduction pathway from the LAA to CS 1 to 2 changed such that it proceeded via the MA, although the conduction pathway from the LAA to CS 7 to 8 was not changed during LAA pacing. Red dots indicate the mitral isthmus ablation line before the ridge ablation. Dotted line arrows indicate the wavefronts of electric conduction resulting from LAA pacing. Brown symbols indicate the MB–LA connection. The ridge ablation site is indicated by the yellow star. ABL indicates ablation catheter; LIPV, left inferior pulmonary vein; and LSPV, left superior pulmonary vein.

bypassing the endocardial MI line, which was successfully treated by ethanol infusion into the VOM. Yoshitani et al reported another case with incomplete MI conduction block,

despite endocardial ablation and ablation inside the CS. In their case, bidirectional MI conduction block was immediately achieved with ablation inside the VOM.⁵ Thus, the MB has an

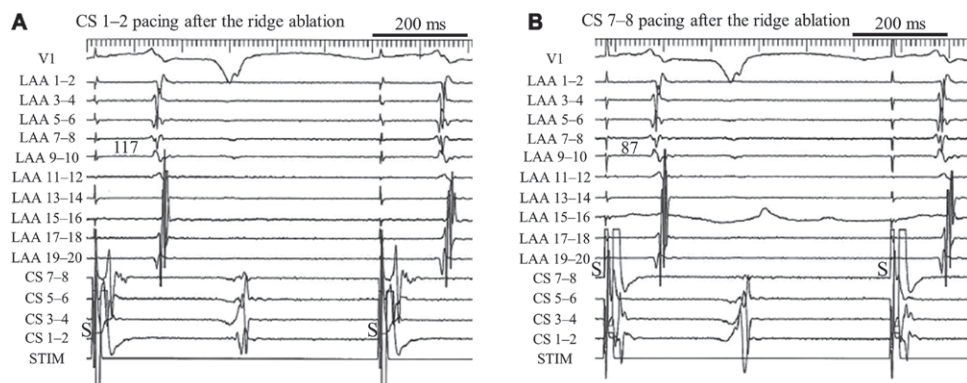


Figure 4. Intracardiac electrograms during coronary sinus (CS) pacing after the ridge ablation. **A**, The conduction time from CS 1 to 2 to the left atrial appendage (LAA) was 117 ms during CS 1 to 2 pacing. **B**, The conduction time from CS 7 to 8 to the LAA was 87 ms during CS 7 to 8 pacing. The activation sequence of the LAA during CS 1 to 2 pacing was equal to the activation sequence of the LAA during CS 7 to 8 pacing.

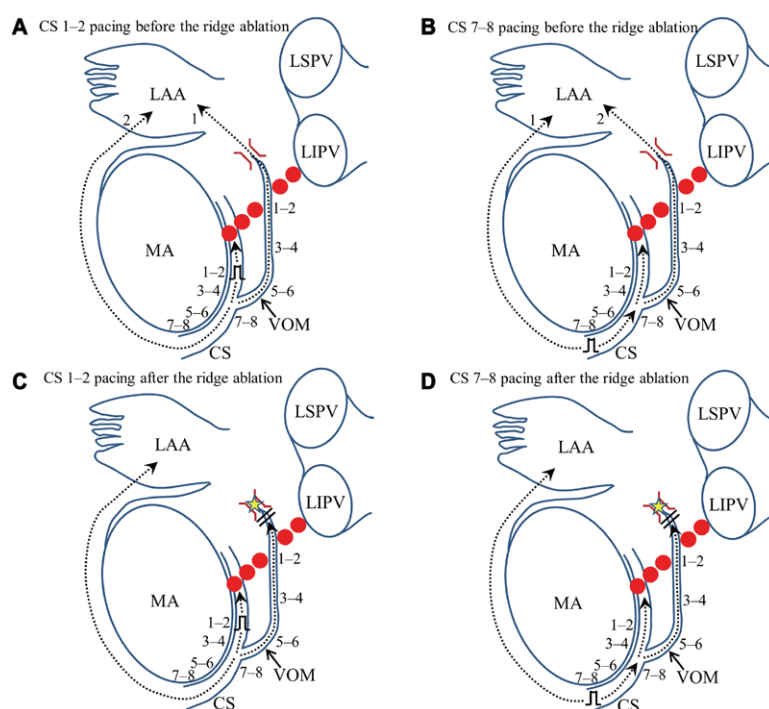


Figure 5. Schematic presentation of the conduction pathway during coronary sinus (CS) pacing before and after the ridge ablation. **A** corresponds to Figure 1C, **B** corresponds to Figure 1D, **C** corresponds to Figure 4A, and **D** corresponds to Figure 4B. After the ridge ablation, the conduction pathway from the CS to the left atrial appendage (LAA) became a single pathway, reflecting the equivalence of the LAA sequences presented in Figure 4. Red dots indicate the mitral isthmus ablation line before the ridge ablation. Dotted line arrows indicate wavefronts of electric conduction resulting from CS pacing. Brown symbols indicate the Marshall bundle-left atrial connection. The ridge ablation site is indicated by the yellow star. The numbers in the LAA indicate the order of wavefronts reaching the LAA. LIPV indicates left inferior pulmonary vein; LSPV, left superior pulmonary vein; MA, mitral annulus; and VOM, vein of Marshall.

important role in the conduction pathway with the perimitral atrial tachycardia. However, there is currently no established method for confirming the presence of an epicardial conduction pathway via the MB. To the best of our knowledge, this is the first report to show that the presence of different LAA activation sequences during pacing from 2 CS sites can help to reveal an epicardial conduction pathway via the MB.

There seem to be 3 methods of creating the MB conduction block: ridge ablation, ablation inside the VOM, and ethanol infusion into the VOM. However, it is technically difficult to insert the ablation catheter into the VOM because it is often absent or thin. Ethanol infusion into the VOM has also been difficult in cases with VOM that are absent, small, or tortuous.³ Meanwhile, ridge ablation does not involve any complex procedure, such as additional catheter cannulation into the VOM. Therefore, ridge ablation is thought to be the best option for the initial procedure to create the MB conduction block. However, if it is difficult to achieve MB conduction block by ridge ablation because of multiple MB-LA connections,⁶ alternative procedures are thought to be preferable, such as ablation inside the VOM or ethanol infusion.

Even when the MI block line is considered to be complete, we should confirm the LAA sequences during pacing from 2 sites in the CS. If 2 different LAA sequences are observed in the presence of complete conduction block of the roof line, we should consider the possibility that an epicardial conduction pathway via the MB is present. In addition, in the case of a slow residual conduction zone within the MI line, 2 different LAA sequences should be observed during pacing from 2 CS sites because the wavefront propagates via 2 different pathways—a clockwise pathway along the MA and a counterclockwise pathway along the MA via the MI residual

conduction zone. It is also important to remember that, in the presence of an MB epicardial conduction pathway, LAA sequences should theoretically be equal if they are assessed during pacing from 2 sites in the distal portion of the CS over the bifurcation of the CS and VOM.

Disclosures

None.

References

1. Jaïs P, Hocini M, Hsu LF, Sanders P, Scavée C, Weerasooriya R, Macle L, Raybaud F, Garrigue S, Shah DC, Le Metayer P, Clémenty J, Haïssaguerre M. Technique and results of linear ablation at the mitral isthmus. *Circulation*. 2004;110:2996–3002. doi: 10.1161/01.CIR.0000146917.75041.58.
2. Shah AJ, Pascale P, Miyazaki S, Liu X, Roten L, Derval N, Jadidi AS, Scherr D, Wilton SB, Pedersen M, Knecht S, Sacher F, Jaïs P, Haïssaguerre M, Hocini M. Prevalence and types of pitfall in the assessment of mitral isthmus linear conduction block. *Circ Arrhythm Electrophysiol*. 2012;5:957–967. doi: 10.1161/CIRCEP.112.971259.
3. Báez-Escudero JL, Morales PF, Dave AS, Sasaridis CM, Kim YH, Okishige K, Valderrábano M. Ethanol infusion in the vein of Marshall facilitates mitral isthmus ablation. *Heart Rhythm*. 2012;9:1207–1215. doi: 10.1016/j.hrthm.2012.03.008.
4. Briceño DF, Valderrábano M. Recurrent perimitral flutter due to vein of Marshall epicardial connections bypassing the mitral isthmus: response to ethanol infusion. *Circ Arrhythm Electrophysiol*. 2014;7:988–989. doi: 10.1161/CIRCEP.114.001631.
5. Yoshitani K, Miyamoto T, Sato Y, Takatsu Y. Another gate keeper to protect the mitral isthmus? Importance of the vein of Marshall. *J Cardiovasc Electrophysiol*. 2015;26:352–353. doi: 10.1111/jce.12576.
6. Han S, Joung B, Scanavacca M, Sosa E, Chen PS, Hwang C. Electrophysiological characteristics of the Marshall bundle in humans. *Heart Rhythm*. 2010;7:786–793. doi: 10.1016/j.hrthm.2010.02.028.

KEY WORDS: atrial appendage ■ atrial fibrillation ■ catheter ablation ■ coronary sinus ■ pulmonary veins